Pagan-Rosado *et al. Sports Medicine - Open* (2025) 11:158
https://doi.org/10.1186/s40798-025-00960-4

Sports Medicine - Open

REVIEW ARTICLE Open Access

Calf Strains in Athletes: A Narrative Review of Management, Injury Grading, and Return to Sport

Robert Pagan-Rosado[1*], Wesley Troyer[2], Raul Rosario-Concepcion[3], Brandon Feaster[4], Sebastian Encalada[5], Brett Kindle[1] and Carles Pedret[6]

Abstract

Background Calf strains are common in sports like football, rugby, and tennis, with high recurrence rates during competition. Despite their frequency, there are no universally accepted guidelines for managing these injuries based on grading systems or imaging modalities. This review aims to evaluate the role of imaging and injury grading in predicting return to sport following a calf strain.

Methods A systematic search was conducted to assess the role of imaging and grading in predicting return to sport in athletes with calf strains. A search of Scopus and PubMed in June 2024 identified relevant studies using terms related to calf strains, imaging, and return to sport. Eligible studies involved human participants, used imaging for diagnosing or grading calf injuries, and assessed return to play outcomes. Studies were excluded if they involved animals, lacked imaging, or did not report relevant outcomes. The screening was done by a team of investigators based on predefined criteria.

Results The review identified that imaging, particularly ultrasound and MRI, offers valuable information for grading calf strains and predicting recovery timelines. Different grading systems correlated with clinical outcomes, but no single modality or grading system was universally superior. Clinical assessments remained essential in return to play decisions.

Conclusions Imaging modalities, along with injury grading, provide useful insights into calf strain severity and recovery. However, these tools should complement clinical assessments, which are the gold standard for return to sport decisions. An integrative approach combining imaging and clinical evaluation is recommended to optimize return to sport protocols. Further standardization of grading systems and imaging protocols may improve prediction accuracy and treatment outcomes for calf strains.

Key Points

1.MRI and ultrasound are essential for diagnosing and monitoring calf muscle injuries, offering insights into injury severity and recovery.

*Correspondence:
Robert Pagan-Rosado
rpaganrosado@gmail.com

Full list of author information is available at the end of the article

© The Author(s) 2025. **Open Access** This article is licensed under a Creative Commons Attribution-NonCommercial-NoDerivatives 4.0 International License, which permits any non-commercial use, sharing, distribution and reproduction in any medium or format, as long as you give appropriate credit to the original author(s) and the source, provide a link to the Creative Commons licence, and indicate if you modified the licensed material. You do not have permission under this licence to share adapted material derived from this article or parts of it. The images or other third party material in this article are included in the article's Creative Commons licence, unless indicated otherwise in a credit line to the material. If material is not included in the article's Creative Commons licence and your intended use is not permitted by statutory regulation or exceeds the permitted use, you will need to obtain permission directly from the copyright holder. To view a copy of this licence, visit http://creativecommons.org/licenses/by-nc-nd/4.0/.

2.Calf injury recovery varies by severity, with rehabilitation progressing from rest to sport-specific exercises, and RTP times ranging from 2 to 12 weeks.
3.Integrating clinical assessments with ultrasound and MRI enhances RTP decision-making, especially for complex injuries, reducing reinjury risks.

Keywords Calf strain, Ultrasound, MRI, Grading, Return to sport, Rehabilitation

Introduction

Calf strains involve the gastrocnemius, soleus, and occasionally the plantaris muscles [1]. These muscles, primarily innervated by the tibial nerve, play a crucial role in plantarflexion and are essential for athletic movements such as walking, running, and jumping [1]. Given their biomechanical features, calf muscles are susceptible to injuries, particularly in sports that require explosive power and endurance, such as football, rugby, and tennis [2]. The prevalence of calf strains is notably high in these sports, with increased incidence and recurrence rates observed during matches and competition [2].

The mechanisms of calf strains vary based on the specific muscle involved [3, 4]. Gastrocnemius strains often result from sudden ballistic movements during knee extension, leading to rapid muscle contraction and potential ruptures at the myotendinous junction [3, 4]. Soleus strains are more common in runners, particularly when running uphill, due to repeated passive dorsiflexion with a flexed knee, presenting as a subacute overuse injury [3, 4]. Plantaris muscle ruptures, although rare, can occur from knee extension combined with ballistic ankle plantarflexion and are frequently associated with traumatic knee injuries [3, 4].

Calf strains have traditionally been graded based on functional limitations and imaging findings. Grade 1 (mild) injuries involve sharp pain but minimal loss of strength and motion, with MRI showing limited muscle fiber involvement [3, 5, 6]. Grade 2 (moderate) injuries cause temporary inability to walk and weakness in ankle movements, with MRI revealing myotendinous junction changes and 10% to 50% muscle fiber disruption [3, 5, 6]. Grade 3 (severe) injuries feature complete muscle disruption and 50% to 100% muscle fiber disruption, visible on MRI [3, 5, 6]. However, this traditional grading system is often considered overly simplistic when evaluating muscle injuries, including calf strains. Modern approaches emphasize more specific classification systems that consider not only the degree of tissue injury but also the functional role of the muscle group involved. These systems may offer a more refined understanding of muscle injuries in general [7].

More recently, Pedret and colleagues proposed one of the few updated grading systems considering specific injury locations and the integrity of the aponeuroses, as well as the synchronous movement between the soleus and medial gastrocnemius [8]. This system shows a significant correlation with return to play (RTP) times and may offer a more accurate estimation of recovery compared to traditional grading systems [8]. Up to this date, there are no universally accepted guidelines for the management of these injuries based on grading systems or imaging. Additionally, there is significant heterogeneity within the literature regarding the imaging protocols utilized to grade these injuries. Given this variability and the lack of standardized approaches, our narrative review can provide an appropriate framework to synthesize the existing evidence, identify patterns and inconsistencies across studies, and help guide consensus on the prognostic value of imaging findings.

The objective of this narrative review is to evaluate the role of imaging and injury grading in predicting the return to sport for athletes with calf strains. We also aim to determine how different imaging modalities—such as ultrasound (US) and MRI—and the grading of the injury based on imaging findings can forecast the timeline and likelihood of recovery for athletes.

Methods

Search Strategy

A comprehensive search of PubMed and Scopus from each database's inception to October 10, 2025, in English was performed. The search strategy was developed and conducted by an experienced librarian with input from the review's principal investigator. Controlled vocabulary combined with keywords was used to answer the question “In athletes with calf strains, what is the role of imaging and grading in predicting return to sport?” The following search terms were combined using Boolean operators (AND/OR): ("calf strain" OR "calf injury" OR "plantaris strain" OR "plantaris injury" OR "gastrocnemius strain" OR "gastrocnemius injury" OR "soleus strain" OR "soleus injury") AND ("ultrasound" OR "ultrasonography" OR "MRI" OR "magnetic resonance imaging") AND ("grading" OR "classification" OR "severity") AND ("return to sport" OR "return to play" OR "recovery" OR "rehabilitation").

Our approach adhered to the Scale for the Assessment of Narrative Review Articles (SANRA) guideline. While we employed systematic search strategies similar to those used in systematic reviews, the narrative review format was deemed most appropriate given the significant heterogeneity in study designs, imaging protocols, and outcome measures across the literature on calf strain

injuries. In addition, selected elements of the PRISMA 2020 guidelines were incorporated to enhance transparency, including the definition of the research question, specification of inclusion and exclusion criteria, identification of information sources, documentation of the search strategy, and reporting of the study selection process. PRISMA items related to quantitative synthesis, risk of bias, and certainty of evidence were not applicable to this narrative design.

Eligibility Criteria and Study Selection

To ensure a comprehensive review of calf strains in athletes, we included studies meeting the following criteria: (1) Research involving human participants of any age and sex/gender who have sustained calf muscle injuries (strains or tears); (2) Participants encompassing various levels of athletic competition, from professional to recreational; (3) Original research utilizing imaging techniques, such as MRI or US, for diagnosing or grading calf muscle injuries; (4) Studies examining imaging methods to predict or assess RTP timelines or outcomes related to calf injuries; (5) Reports detailing injury severity, including imaging findings, RTP criteria, recovery duration, and functional outcomes; (6) Inclusion of prospective or retrospective cohort studies, case–control studies, randomized controlled trials, and relevant cross-sectional studies; (7) Studies published in peer-reviewed journals or conference proceedings, with no restriction on publication year.

Studies were excluded based on the following criteria: (1) Research involving animals or cadaver specimens; (2) Studies focusing on conditions other than calf muscle injuries, such as isolated Achilles tendon injuries; (3) Research that did not utilize imaging techniques for assessing calf muscle injuries; (4) Studies using imaging exclusively for non-diagnostic purposes; (5) Research lacking specific outcome measures related to calf muscle injury severity or imaging findings; (6) Publications that do not specifically address calf muscle injuries but rather general musculoskeletal injuries; (7) Narrative reviews, systematic reviews, meta-analyses, opinion pieces, and editorials; (8) Conference abstracts or posters without full-text access; (9) Non-English language studies, unless translations were available; (10) Duplicate publications or studies reporting redundant data.

The articles were screened by R.P.R, W.T., R.R.C., and B.F. based on title and abstract. Once the initial screening was complete to remove articles based on the criteria above, full text review was conducted by R.P.R., W.T., R.R.C., and B.F. to determine eligibility based on inclusion criteria or for further review when the abstract and title did not provide this information. An additional investigation through cited references of included articles was also completed by R.P.R., W.T., and R.R.C., and no additional articles were identified. For any articles in which there was uncertainty about the appropriateness of inclusion, a review was conducted by R.P.R.

Results

Thirty-one articles were retrieved through a comprehensive database search. Of those, eleven articles met the inclusion criteria for analysis. Figure 1 highlights the search strategy for studies included in this review. A summary of the included articles is found in Tables 1 and 2. Seven articles were retrospective studies, while the rest were divided among cross-sectional, case–control, and descriptive epidemiologic studies. Nine studies focused on describing imaging findings (on ultrasound and/or MRI) and grading of calf injuries and their association with time to return-to-play (RTP). The remaining two articles were focused on specific imaging findings including fiber orientation, and tissue stiffness among other additional changes that are prevalent in acute and subacute calf injuries.

Discussion

Imaging Protocols for Calf Injuries

Although a calf injury diagnosis can be established with a thorough history and physical examination, imaging can provide valuable information regarding the extent and severity of the injury. MRI and US are the most common imaging modalities used to assess calf muscle injuries, as they both can confirm the presence of a strain, localize the specific muscle(s) involved, and quantify the extent of injury through grading systems. Of the 11 studies, 7 examined MRI only, 3 US only, and 1 study included both MRI and US evaluation. US imaging protocols were similar for all 4 studies involving ultrasound: each highlighted patient position, transducer orientation, and identification of anatomical structures to be evaluated. Patients were commonly placed in the prone position with scanning beginning at the popliteal fossa and progressing distally to the insertion of the gastrocnemius-soleus complex at the Achilles tendon. Only 1 out of the 4 studies utilizing US examined the structures in both short and long axis [8]. Dynamic and passive evaluations were performed in 3 out of 4 studies with the ankle held in the neutral position, dorsiflexion and plantarflexion [8–10]. Timing of US examination differed between studies, with some performing assessments immediately post-injury while others conducted evaluations throughout the rehabilitation phase to monitor recovery progress up to the 6-week mark [10, 11]. Two of the 4 US studies did not specify timing of evaluation in relation to the onset of injury [8, 9].

Ten of 11 studies included a retrospective component regarding radiographic imaging review. Of the 10 studies that included retrospective imaging review, 9 included

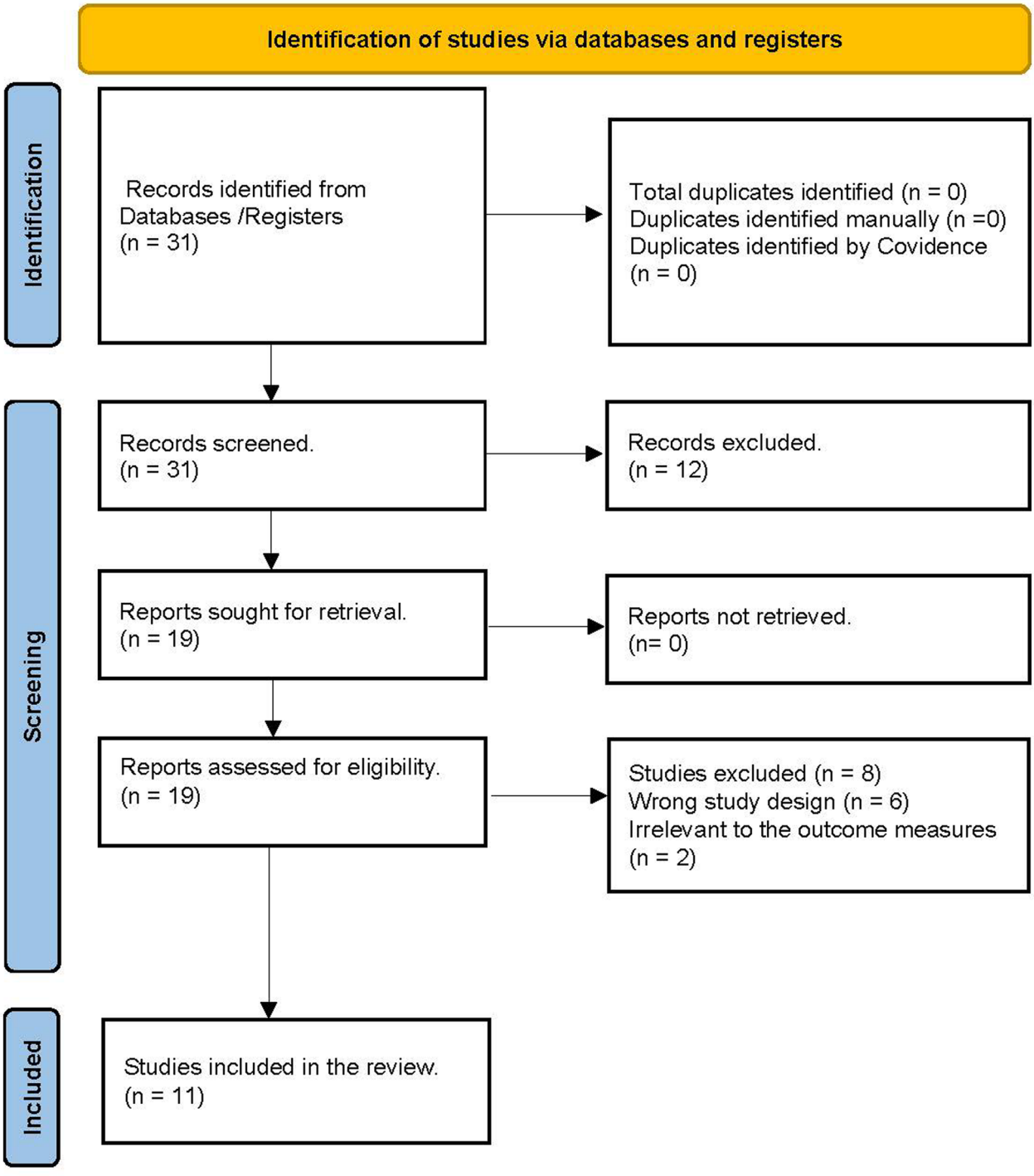

Fig. 1 PRISMA flow diagram for systematic reviews [29]

a description of how radiologists interpreted images (except for studies by Green et al. 2020 and Green et al. 2019) [12, 13]; however only 4 of the 10 included specific standardized protocols for how radiologists performed said imaging [8, 9, 11–14]. Implementation of standardized protocols was possible due to the cross-sectional nature of these studies and was most often performed while following chronic injuries and in studies assessing injury recurrence [9, 11, 14]. One retrospective study was able to implement a standardized, systematic protocol using static and dynamic US evaluation of medial gastrocnemius tears [8]. Three of 4 studies involving US included static and dynamic evaluation of the site of injury; however, 1 study that included elastography

Table 1 Study Characteristics

Study	Study design	Sample size (injuries)	Participant characteristics	Sport	Injury type
Gastrocnemius injuries					
Nielsen et al. [9]	Cross-sectional	10	Mean 45.3 ± 8 yrs (30–58); 70% M, 30% F; Amateur	Soccer, tennis, badminton, rugby, dance, running, CrossFit	Chronic gastrocnemius strain (mean duration 47 ± 25 months)
Green et al. [12]	Case–control	149 (114 index, 35 recurrent)	Median 25 yrs (18–33); All M; Professional	Australian Football League	CMSI (51% w/ AD; 96% SOL or gastrocnemius)
Green et al. [13]	Descriptive epidemiologic	184 (149 players)	Median 25 yrs (18–33); All M; Professional	Australian Football League	CMSI
Martínez-Rodríguez et al. [11]	Cross-sectional	21	Mean 44 ± 8 yrs; 67% M, 33% F; Recreational	Running	Grade 1–2 dist MG strain at MTJ
Pedret et al. [8]	Retrospective case–control	115 (64 athletes, 51 workers)	Athletes: 40.7 ± 9.6 yrs, 84% M; Workers: 48.7 ± 8.1 yrs, 67% M; 62% professional, 39% recreational	Running (31%), paddle tennis (31%), soccer (16%)	MG tears
Werner et al. [17]	Retrospective case series	27 injuries (24 players)	Mean 27.2 yrs (22–35); All M; Professional	American Football (NFL)	Acute gastrocnemius-SOL complex tears
Soleus injuries					
Pedret et al. [14]	Retrospective Case series	44 (from 61 athletes, 17 excluded)	Mean 31.85 ± 7.45 yrs; High-level/professional	Soccer, tennis, track and field, basketball, triathlon, field hockey	SOL strain
Pezzotta et al. [10]	Retrospective observational	20	18–40 yrs (27.4 ± 4.2); All M; Professional	Football	Acute SOL strains and tears
Prakash et al. [6]	Retrospective	114 tears (100 patients)	20–50 yrs; 89% M, 11% F; Professional and semi-professional	Football, soccer, rugby, hockey, running	Acute calf tear
Sergot et al. [15]	Retrospective case series	28 injuries (21 players)	18–36 yrs; Professional	Rugby	Acute calf tear
Waterworth et al. [16]	Retrospective cohort	57 abnormal (63 total cases)	Professional; All M	Rugby	Gastrocnemius-SOL strains

AD aponeurotic disruption, *CMSI* calf muscle strain injury; dist, distal, *F* female, *M* male, *MG* medial gastrocnemius, *MTJ* myotendinous junction, *SOL* soleus, *w/* with, *yrs* years

assessment only included static evaluation of the ankle held in plantarflexion [8–11]. Most often, a 4–14 Hz linear US transducer was utilized within 48–72 h of injury. Two of the four studies utilized follow-up US for interval assessment of chronic injuries while the other two utilized US in the acute setting. Of the 2 studies performed in the acute setting, one utilized US diagnostically and the other as a screening tool that was ultimately followed up with an MRI [8–11]. One study strongly supported use of US only as a screening tool given its low sensitivity for soleus lesions [10]. Nielsen et al. in particular found US to be useful in monitoring progress in chronic gastrocnemius tears but not soleus lesions given their deep location [9].

Eight of 11 studies utilized MRI [6, 10, 12–17]. Of the 8 studies involving MRI, 2 did not mention or include specific standardized imaging protocols. The 6 studies that did include imaging protocols differed across sites. Two of the 6 studies utilized 1.5 T machines, 2 3.0 T machines, 1 a combination of 1.5 T machines early in the study, and 3.0 T thereafter, and one study did not specify whether 1.5 versus 3.0 T machine was used [6, 10, 14–17]. Three of six studies that described specific imaging protocols included axial, coronal and sagittal fast-spin-echo T1 weighted images with 2–5 mm slice thickness [10, 14, 17]. Pezzotta et. al included either STIR or fat-suppressed T2 weighted images along with axial fast-spin-echo T2 weighted sequences [10]. The other 3 studies implemented standard protocols using axial, coronal, and sagittal proton density (PD) and proton-density fat saturated images [6, 15, 16]. Three studies specifically mentioned the number of radiologists involved in interpretation of MRI findings; however, only one study assessed inter-observer agreement amongst radiologists assigned Olympic Park Classification, Munich and British Athletics Muscle Injury Classification (BAMIC)

Table 2 Imaging Findings and Return to Play Outcomes

Study	Imaging findings	RTP time	RTP criteria	Key findings related to imaging and RTP
Gastrocnemius injuries				
Nielsen et al. [9]	US: Shortened fascicles at dist central position (11.0 mm shorter, p = 0.004); increased aponeurotic thickness during contraction (1.4 mm, p = 0.02)	N/A (chronic)	N/A	Chronic calf strain causes long-term structural changes including shortened fascicles, thickened aponeuroses, and altered activation patterns. Dynamic US indicates injury site does not actively produce contractile force
Green et al. [12]	MRI: 50.8% SOL injuries w/ AD; gastrocnemius edema length 82.5 ± 50.8 mm (MG) and 51.4 ± 26.7 mm (LG); 41.2% mild and 11.7% severe AD in gastrocnemius	No AD: 19.4 ± 10.8 days; Mild AD: 26.7 ± 16.8 days; Severe AD: 31.3 ± 12.6 days; Myofascial: 16 ± 5.6 days	Pain-free walking, running > 90% max speed, full training, RTP	AD increased RTP by 8.4 days avg (p = 0.007). Anatomical location not associated w/ RTP time. Mechanism of injury and MRI evidence of AD inform RTP prognosis
Green et al. [13]	MRI: SOL injuries more prevalent than gastrocnemius; 91.4% of re-injuries involved SOL	Index: 2–102 days; Re-injuries: + 16.6 days to run > 90%, + 18.9 days to RTP vs index; Running-related: 33.4 ± 21.6 days; Non-running: 21.3 ± 15.1 days	Pain-free walking, running > 90% max speed, full training, RTP	Re-injuries occurred mostly within 2 months, almost exclusively SOL, and required sig longer recovery. Running-related injuries took longer to recover than non-running injuries
Martínez-Rodríguez et al. [11]	US: Sig differences in relative elasticity (SR) between injured and healthy legs (p < 0.001); heterogeneous image w/ increased stiffness between epimysial planes	N/A	N/A	Valid prognosis should be based on clinical/functional parameters (absence of pain on palpation, flexibility, strength, neuromuscular patterns) and sport-specific activities performed asymptomatically
Pedret et al. [8]	US: Type 1 (myoaponeurosis): 14.1% athletes, 29.4% workers; Type 2A (aponeurosis < 50%): 40.6% athletes, 54.9% workers; Type 2B (> 50%): 15.6% athletes; Type 3 (free GA tendon): 20.3% athletes, 2% workers; Type 4 (mixed): athletes only	Mean 39 ± 18 days; sig relationship between injury grade and RTP/RTW (p < 0.001)	Return to previous activity without restriction	Type 2 injuries most frequent. Dynamic exam important—asynchronous movement predicts longer RTP. Types 3 and 4 have worst prognosis. Intermuscular hematomas occur in types 2 and 4. Classification system is prognostic for RTP
Werner et al. [17]	MRI (n = 14): 93% had < 50% cross-section w/ edema; 86% had fascial tears (92% deep between gastrocnemius-SOL); 42% w/ fascial retraction; mean fascial defect 18 ± 16 mm (3–62 mm)	Overall: 17.4 ± 14.6 days (3–62); MRI cohort: 22.8 ± 17.7 days vs no MRI: 12.9 ± 5.9 days (p = 0.07)	Full unrestricted practice or game participation	RTP > 2 weeks associated w/ larger AP fascial defect size (p = 0.032) and fluid collection (p = 0.031). Age, position, number of injured muscles, and presence of fascial defect not correlated w/ RTP > 2 weeks
Soleus injuries				
Pedret et al. [14]	MRI: 72.7% MT, 27.3% MF; MT: 29.5% med, 15.9% central, 27.3% lat; MF: 18.1% ant, 9.2% post; sig correlation w/ age (p < 0.001), craniocaudal retraction (p < 0.03), AP retraction (p < 0.05)	Mean 29.1 ± 18.8 days; central MT ~ 25 days longer than lat MT (p = 0.044)	Not specified	Central tendon SOL injuries have longer RTP than other locations. Extent of retraction/gap more important than edema extent for prognosis
Pezzotta et al. [10]	US and MRI: 70% right, 30% left; 55% med, 40% central, 5% lat; 60% prox third; aponeurosis affected in 13, MF in 6, MTJ in 1; edema in all, gap/retraction in 11; Munich: 11 type 3A, 8 type 3B, 1 type 4; BAMIC: 11 grade 1, 4 grade 2, 4 grade 3, 1 grade 4	Mean 3.3 ± 1.6 weeks; both classification systems correlated w/ RTP (p < 0.0001)	Return to normal sports activity w/ minimum reinjury risk	Both Munich and BAMIC correlated w/ RTP; BAMIC offers better prognostic value as it includes edema evaluation. Edema extent is strongest prognostic factor. Central tendon/MF lesions have worse prognosis. MRI needed for proper risk stratification
Prakash et al. [6]	MRI: 69.3% SOL, 27.2% MG, 3.5% LG; 54.4% prox SOL, 45.6% dist SOL; variable aponeurotic involvement	Grade 0: 8.1 ± 7.45 days; Grade 1: 17.17 ± 8.84 days; Grade 2: 24.69 ± 9.71 days; Grade 3: 48 ± 15.95 days	Return to full competition	MRI-detected connective tissue injury associated w/ longer RTP. Clear progression of RTP time w/ increasing injury grade

Table 2 (continued)

Study	Imaging findings	RTP time	RTP criteria	Key findings related to imaging and RTP
Sergot et al. [15]	MRI: 10 MG, 1 LG, 17 SOL	Range 5–110 days (mean 40.1 ± 26.4); MF interface: 20.1 days vs tendon/aponeurosis: 46.8 days (p = 0.02)	Full unmodified training session w/ match loads	MF interface injuries had shorter RTFT and lower grades compared to tendon/aponeurosis injuries (p < 0.05). Olympic Park classification showed moderate-strong correlation w/ RTFT (weaker than Munich/BAMIC)
Waterworth et al. [16]	MRI: 62% SOL (84% at MTJ), 24% gastrocnemius; 81% prox calf; 38% w/ intramuscular tendon tear; 56% w/ intermuscular fluid	Multiple injuries: 88% missed ≥ 1 game vs single: 47% (p = 0.017); intramuscular tendon tears: strongly associated w/ missed games (p = 0.010)	Games missed	Multiple involvement, MTJ strain location, and intramuscular tendon tears predict missing games. Deep strain location correlates w/ games missed (p = 0.036). Intermuscular fluid not prognostic. Strain size parameters not sig correlated w/ games missed

AD aponeurotic disruption; ant, anterior, *AP* anteroposterior, *avg* average, *BAMIC* British Athletics Muscle Injury Classification, *CMSI* calf muscle strain injury; dist, distal, *F* female, *GA* gastrocnemius aponeurosis, *lat* lateral, *LG* lateral gastrocnemius, *M* male, *med* medial, *MF* myofascial, *MG* medial gastrocnemius, *MRI* magnetic resonance imaging, *MT* myotendinous, *MTJ* myotendinous junction; post, posterior; prox, proximal, *RTP* return to play, *RTFT* return to full training, *RTW* return to work; sig, significant/significantly, *SOL* soleus, *SR* strain ratio, *US* ultrasound, *w/* with, *yrs* years

score/grade [10, 15, 16]. This study exposes an inherent flaw amongst all grading systems, i.e. subjectivity of interpretation. For example, Sergot et. al highlighted how myofibril detachment and connective tissue failure are not objectively defined and thus open to subjective interpretation [15]. This was also exhibited in the Waterworth et al. study where the subjectivity of interpretation was mitigated by having the most senior radiologist interpretation predominate [16].

Acute Management and Rehabilitation

In the acute phase, management should focus on limiting potential complications such as hemorrhage and breakthrough pain. Initial management decisions should be based on the extent of injury, which considers the athlete's subjective complaints and objective findings on exam and imaging. Fortunately, a low threshold is maintained for ordering advanced imaging in elite athletes, given the financial and strategic consequences of improper management, which has been noted to increase RTP timelines by up to two weeks [18]. Most experts agree that the first 24–48 h to a week post-injury is an appropriate time to employ advanced imaging protocols including both MRI and US [8, 18].

Muscle rest is critical during the initial 3–5 days following injury. R.I.C.E (rest, ice, compression, elevation) is a commonly used method in the acute phase for pain management [19]. Use of non-selective NSAIDs is generally not recommended within the first 24–72 h following injury given increased bleeding risk from anti-platelet effects [4]. Instead, acetaminophen and selective COX-2 inhibitors such as celecoxib can be utilized during this time window [20]. Gentle active range-of-motion exercises and isometric contractions may also be introduced to maintain some degree of muscle activation without causing further tearing of muscle fibers [4, 18]. If the athlete fails to exhibit signs of clinical improvement, further imaging studies should be obtained, as improper management of calf muscle injury predisposes the athlete to recurrence and ultimately longer RTP time [4, 18].

The duration of the acute rehabilitative phase varies depending on the severity of the strain but typically spans the first 2–3 days to 2 weeks, or until the athlete can complete weight-bearing activities without an antalgic gait [4, 21]. Red flag signs and symptoms should be reviewed with the athlete, especially if the injury occurred in the setting of significant trauma, which may increase the risk of developing acute compartment syndrome or deep venous thrombosis (DVT). Moreover, athletes should monitor for the classic triad for DVT (worsening pain, swelling, and tenderness) as well as hallmark signs of acute compartment syndrome (pain disproportionate to injury, pallor, paresthesia, palpable tenseness, and pulselessness) [22]. Of note, DVT can happen in up to 6–20% of patients in addition to medial gastrocnemius and soleus muscle pathology and should not be viewed solely as an alternative diagnosis [23, 24]. Occasionally, high grade injuries may benefit from a tall walking boot or crutches to assist with ambulation [25]. Injuries with loss of synchronicity of the gastrocnemius and soleus complex, may also benefit from a period of immobilization or aspiration of hematoma separating the two muscles to decrease fibrotic scar tissue between the layers and potentially decrease risk of reinjury.

Treatment decisions and algorithms are highly context-dependent for each athlete. Although there is a lack of consensus for optimal management strategies in the literature, there is agreement that the athlete should progress in a stepwise fashion based on the severity of the injury [18]. Early-loading strategies most often begin with 2–3 weeks of light calf stretches and isometric single-leg calf raises to optimize muscle capacity. Once the athlete can perform single leg heel raises comfortably, light walking and eccentric strengthening exercises can be performed during week 3 or 4 post-injury. The athlete may also start light strengthening exercises with both

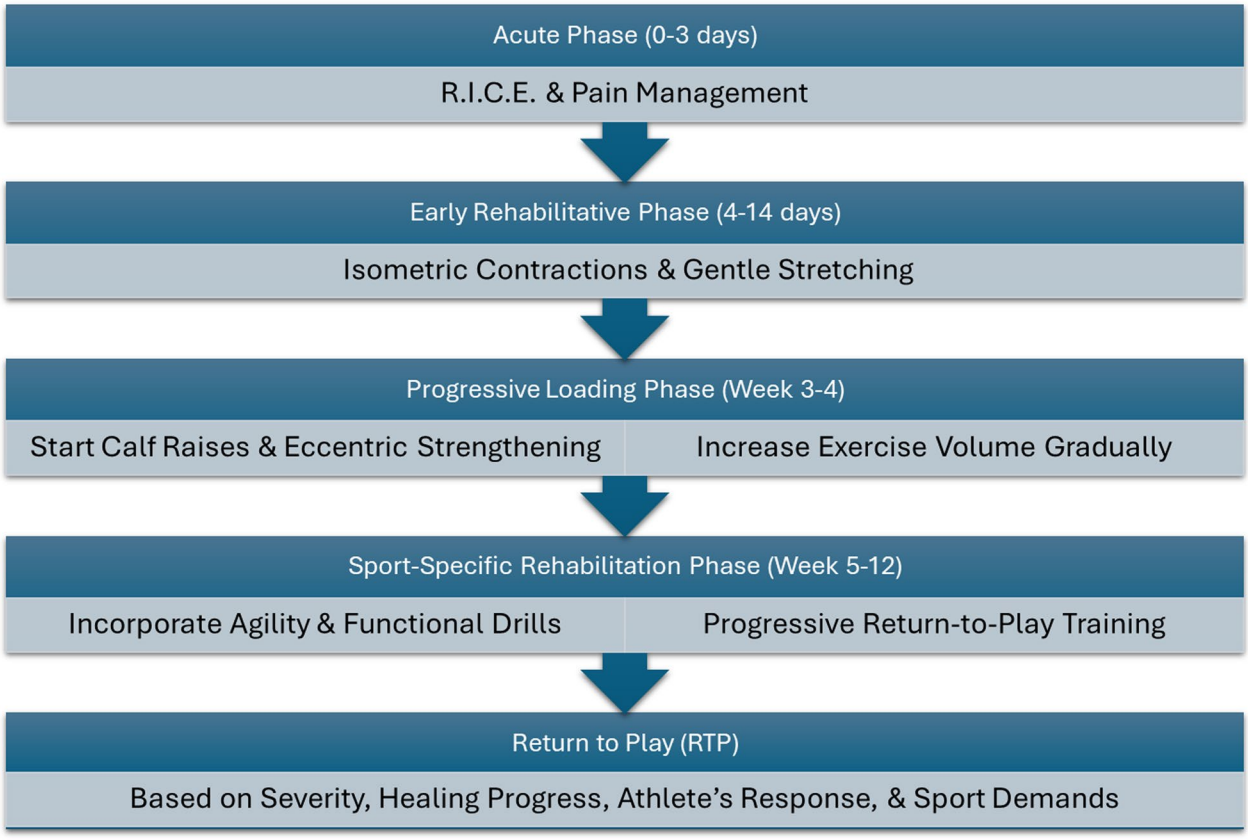

Fig. 2 Flowchart summarizing the key stages in the rehabilitation process for calf strains, outlining the progression from the acute phase to return to play

knees extended and flexed to target the gastrocnemius and soleus muscles respectively. The athlete may subsequently increase exercise volume following the principles of progressive loading. This phase can extend from week 3 to month 2 post-injury, contingent on the individual's progress [4, 21].

The final phase of rehabilitation involves a gradual progression of exercises and functional activities. A key component is the incorporation of sport-specific movements and agility drills to ensure that the calf muscles are adequately prepared for the demands of the chosen activity [4, 21]. The timeline for RTP varies widely and is contingent on factors such as the injury severity, individual healing rates, positional demands of the athlete and sport, as well as the effectiveness of the rehabilitation program [4, 21].

In general, mild to moderate injuries may benefit from an accelerated rehabilitation course (2–6 weeks) versus those with severe injuries who will likely benefit from a 6–12-week rehabilitation course. Management for mild to moderate injuries is nearly identical for severe injuries but with an accelerated time course. Surgical consultation is warranted for severe strains, cases with prolonged pain in the setting of a contracture, or significant intramuscular hematomas with secondary compartment syndrome [19]. Figure 2 presents a flowchart summarizing the key stages in the rehabilitation process for calf strains, outlining the progression from the acute phase to RTP.

Injury Grading and Practical Implications

There is no specific imaging factor that has been linked to determining RTP after calf strain. As such, clinical factors remain the gold standard for evaluating an athlete's readiness to return to competition. Reliance on clinical assessment underscores the importance of a thorough, multifaceted approach to RTP, balancing subjective evaluation with emerging objective measures [26]. The absence of localized discomfort on palpation and weakness of calf muscles on examination is essential. Obtaining advanced imaging, specifically MRI, should be considered for additional support of clinical decision-making and ruling out concomitant injuries or prolonged symptoms. If the injury is seen to involve multiple muscles, both the gastrocnemius and soleus muscles or if there is tendinous involvement, a prolonged RTP program should be considered [12]. Reinjury risk is highest within the first 2 months of initial injury, likely due to premature RTP in the setting of tissue immaturity [27]. Thus, frequent re-evaluation of the calf should be administered to the athlete throughout this period. Such an

integrated approach can help cultivate an individualized rehabilitation strategy and successfully return the athlete to play.

While a consensus protocol for evaluating and determining RTP timelines for calf injuries is still in development, a validated framework exists for hamstring injuries known as the BAMIC. The BAMIC grades injuries based on severity, focusing on the affected muscle portion (myofascial, myotendinous, or tendinous), the degree of edema, and the cross-sectional area of fiber disruption as observed on MRI. Follow-up studies have shown that these classifications appropriately correlate with estimated RTP durations [28]. A study involving elite track and field athletes showed that increased BAMIC classifications were associated with longer recovery periods and that the suggested rehabilitation based on BAMIC classification of hamstring injuries resulted in low rates of reinjury [28]. There have been attempts to modify the BAMIC framework for calf muscle injury. Prakash et al. developed the Olympic Park Classification which similarly classified injuries based on connective tissue framework although notably did not further subclassify injuries based on the component that was injured (ie proximal, middle, or distal portions) [6]. Although the Olympic Park system was positively associated with RTP duration, it has yet to be tested in other populations or non-elite athletes. Such classification schemes as the Olympic Park system are promising yet lack the appropriate power and generalizability to validate their effectiveness [6].

Pedret and colleagues studied injury locations related to the medial head of the gastrocnemius in 115 subjects, proposing five injury types linked to RTP and work [8]. They found that injuries involving the free gastrocnemius aponeurosis resulted in longer recovery times [8]. Additionally, involvement of more than 50% of the aponeurosis width, intermuscular hematoma, and asynchronous gastrocnemius-soleus motion correlated with worse outcomes [8]. This classification system has been shown to have a linear correlation with RTP time in athletes regarding muscle injury grade and may provide a more accurate RTP estimation compared to traditional grading systems.

Return to Sport

Based on our comprehensive review of the available literature, RTP times were found to vary significantly depending on the nature and severity of the injury. Overall, the time to RTP ranged widely from 2 to 102 days, with an average of 39 ± 18 days across different injury types [13].

Injuries categorized by the Olympic Park system by severity have been shown to correlate with RTP times [6]. Grade 0 injuries resulted in the quickest recovery, with players returning within 0 to 20 days (mean: 8.1 ± 7.45 days) [6]. Grade 1 injuries followed had a mean RTP of 17.2 ± 8.84 days, while Grade 2 injuries took longer, averaging 24.7 ± 9.71 days [6]. Grade 3 injuries exhibited the longest recovery, with an average RTP of 48 ± 15.95 days [6]. This clear relationship between injury grade and recovery time suggests that athletes sustaining more severe injuries have involvement of denser connective tissue such as tendons or aponeuroses, which may lead to extended recovery times. However, it remains challenging to distinguish between mild to moderate injuries and their precise correlation with RTP times, as these injuries may vary in severity and recovery dynamics.

As mentioned previously, injuries with aponeurotic disruption were associated with longer RTP times compared to those without disruption [15]. A study of English Premiership rugby players with calf injuries found that injuries located at the myofascial interface had a significantly shorter recovery time to full training compared to those affecting tendons or aponeuroses, averaging 20.1 days versus 46.8 days ($p = 0.02$) [15]. Moreover, a study of Australian Rules football players demonstrated that calf injuries without aponeurotic disruption took about 19.4 days on average, while mild and severe disruptions increased the average recovery time to 26.7 and 31.3 days, respectively [12]. This same study also showed that myofascial injuries displayed the shortest recovery times, averaging 3 days to achieve pain-free walking, 12 days to achieve running at > 90% of maximum speed, 14 days to return to full training, and 16 days for RTP [12].

The mechanism of injury also plays a crucial role. Injuries occurring during high-impact activities such as running generally required more time to recover, averaging 33.4 days, compared to 21.3 days for injuries sustained during lower-impact activities [13]. Additionally, re-injuries led to longer recovery periods, with players taking an extra 16.6 days to reach > 90% running speed and 18.9 days to RTP compared to their initial injuries [13].

A specific focus on soleus and gastrocnemius strains revealed further insights into recovery dynamics. One study identified the presence of edema and involvement of the soleus central tendon on MRI as an independent prognostic factor for the duration of RTP [14]. Pedret et al. demonstrated that asynchronous motion at the injury site of the gastrocnemius and soleus muscles, observed through dynamic US scanning, is a poor prognostic indicator for early return to baseline activity and sport, in contrast to synchronous motion [8]. Among players with isolated soleus strains, 59% missed at least one game, while a lower percentage of those with gastrocnemius strains missed games [14]. Soleus strains were particularly common among those missing games, emphasizing the severity of this injury type [14]. Interestingly, injuries to the central myotendinous junction of the soleus, in isolation, resulted in a longer RTP time (approximately

25 days more) compared to those at the lateral myotendinous junction [14]. However, it is important to note that this difference is likely attributable to the dominance of the aponeurosis involved. For example, in a soleus muscle with a lateralized central tendon, a thin lateral aponeurosis, and a larger, thicker medial aponeurosis that spans most of the muscle belly, the prognosis for injury would be worse if the medial aponeurosis is affected, as it is the dominant structure in this muscle. Nonetheless, this study found a significant correlation between age and both craniocaudal and anteroposterior retraction with prolonged RTP [14].

Future Directions

Future research should continue to explore the correlation between imaging findings, clinical data, and appropriate RTP protocols, with the goal of developing a consensus and validated grading system, like the BAMIC system used for hamstring injuries. Specifically, such research should focus on identifying candidate prognostic factors, which would then require rigorous internal and external validation before informing clinical practice. This system should incorporate factors specific to calf injuries, such as denser soft tissue structures, which may require unique considerations in grading the severity of injuries. Research should explore how imaging can help in identifying structural changes in the calf muscles, including the gastrocnemius and soleus, throughout the healing process.

Additionally, more studies are needed to evaluate reinjury rates, particularly in the soleus muscle, as it is often more challenging to assess its recovery clinically during early stages post-injury. The use of advanced imaging tools could provide valuable insights into muscle recovery and help track progress, allowing clinicians to adjust treatment protocols accordingly. Furthermore, research should investigate the role of aspiration of hematomas in calf injuries, particularly when the muscle layers are disrupted. Aspiration may help approximate the muscle fibers and prevent the formation of fibrotic scar tissue, potentially improving muscle synchronicity and reducing reinjury risk. Moreover, the use of walking boots could also be explored to enhance muscle synchronization during the recovery process.

Finally, studies should continue to assess the reinjury risk associated with maladaptive neuromuscular patterns that often emerge during rehabilitation. These patterns can lead to compensations that place additional strain on other parts of the body and increase the likelihood of subsequent injuries.

Limitations

The current evidence for using imaging to predict return to sport after calf injuries has limitations. The majority of the included studies were retrospective, which introduces potential selection bias and makes it difficult to establish clear causal links between imaging findings and RTP outcomes. There is significant variability in imaging protocols across the studies. Out of the nine studies using MRI, only six described specific imaging sequences and protocols, and just two (Pezzotta et al. [10] and Sergot et al. [15]) explicitly assessed interobserver reliability. Interobserver reliability was only fair to moderate, raising concerns about classification consistency in clinical practice.

Sample sizes were generally small, with seven of eleven studies including fewer than 50 injuries with complete imaging data. This limits the statistical power to identify predictive imaging features and raises the risk of a type 2 error. Most studies focus solely on elite or professional athletes from a single sport, reducing their relevance to recreational athletes who may differ in tissue-healing capacity, training demands, and RTP criteria. Nine out of eleven studies involve exclusively or mostly male athletes, leaving sex-specific differences in calf injury patterns and recovery pathways underexplored.

Rehabilitation protocols were neither standardized nor adequately described in any of the included studies, creating unmeasured variables that could influence RTP timelines independently or imaging findings. Definitions of RTP vary widely, from being free to walk, to returning to full training, to participating in competitive matches, or reaching pre-injury performance levels, making direct comparisons difficult and limiting the ability to synthesize evidence about the prognostic value of imaging. The lack of consensus on RTP further complicates clinical applications. Finally, only two studies (Green et al. [13] and Pedret et al. [8]) reported recurrence rates, and neither examined whether imaging findings predict long-term outcomes or the risk of reinjury beyond the initial RTP.

Conclusion

This review highlights the potential role of imaging as it relates to the return to sport for athletes following calf muscle strains. While current imaging classifications show promise in determining RTP, they are better utilized to supplement comprehensive clinical assessment as this remains the gold standard for RTP. These results continue to emphasize the need for an integrative approach to ensure effective and safe RTP protocols for athletes based on injury grading.

Abbreviations

PRISMA	Preferred Reporting Items for Systematic Reviews and Meta-Analyses
US	Ultrasound
MRI	Magnetic Resonance Imaging
RTP	Return to play
R.I.C.E.	Rest, ice, compression, elevation

NSAIDs	Non-steroidal anti-inflammatory drugs
COX-2	Cyclooxygenase-2
DVT	Deep venous thrombosis
BAMIC	British Athletics Muscle Injury Classification
STIR	Short-Tau inversion recovery
PD	Proton density

Acknowledgements
We would like to extend our sincere appreciation to Jessica Truett for her support and valuable contributions.

Author contributions
RP-R: Conceptualization, Literature Search, Data Curation and Synthesis, Writing- Original Draft Preparation, Writing- Review and Editing; WT: Conceptualization, Data Synthesis, Writing- Original Draft Preparation, Writing- Review and Editing; RR-Concepcion: Conceptualization, Data Synthesis, Writing- Original Draft Preparation, Writing- Review and Editing; BF: Data Curation, Writing- Original Draft Preparation; SE: Methodology, Visualization; BK: Writing- Review, Editing, and Supervision; CP: Conceptualization, Validation, Writing- Review, Editing, and Supervision.

Funding
This review was funded by a grant from the State of Florida Department of Health.

Availability of data and materials
All data supporting the findings of this review are available publicly and within the article.

Declarations

Ethics approval and consent to participate
Not applicable.

Consent for publication
Not applicable.

Competing interests
The authors declare that they have no financial or commercial conflicts of interest. Recommendations and content in this narrative review are based solely on the available evidence. The authors acknowledge that their professional focus includes research in musculoskeletal imaging, which may represent a potential source of perspective. Carles Pedret is an Editorial Board member of Sports Medicine but was not involved in the selection of peer reviewers for this manuscript or any of the subsequent editorial decisions.

Author details
[1]Andrews Institute for Orthopedics and Sports Medicine, 3527 Gulf Breeze Pkwy, Gulf Breeze, FL 32561, USA
[2]Department of Physical Medicine and Rehabilitation, Division of Sports Medicine, Mayo Clinic, Jacksonville, FL, USA
[3]Division of Physical Medicine and Rehabilitation, Baptist Health South Florida, Miami, FL, USA
[4]Department of Physical Medicine and Rehabilitation, Mayo Clinic, Rochester, MN, USA
[5]Department of Pain Medicine, Mayo Clinic, Jacksonville, FL, USA
[6]Sports Medicine and Imaging Department, Clinica Diagonal, Esplugues de Llobregat, Spain

Received: 3 March 2025 / Accepted: 25 November 2025
Published online: 12 December 2025

References

1. Moore KL, Dalley AF, Agur AM. Clinically oriented anatomy. 7th ed. Lippincott Williams & Wilkins; 2013.
2. Green B. Pizzari t calf muscle strain injuries in sport: a systematic review of risk factors for injury. Br J Sports Med. 2017;51:1189–94.
3. Bryan Dixon J. Gastrocnemius vs. soleus strain: how to differentiate and deal with calf muscle injuries. Curr Rev Musculoskelet Med. 2009;2(2):74–7.
4. Meek WM, Kucharik MP, Eberlin CT, Naessig SA, Rudisill SS, Martin SD. Calf strain in athletes. JBJS Rev. 2022;10(3):e21.00183. https://doi.org/10.2106/JBJS.RVW.21.00183.
5. Lee JC, Mitchell AW, Healy JC. Imaging of muscle injury in the elite athlete. Br J Radiol. 2012;85(1016):1173–85.
6. Prakash A, Entwisle T, Schneider M, Brukner P, Connell D. Connective tissue injury in calf muscle tears and return to play: MRI correlation. Br J Sports Med. 2018;52(14):929–33.
7. Balius R, Pedret C, Kassarjian A. Muscle madness and making a case for muscle-specific classification systems: a leap from tissue injury to organ injury and system dysfunction. Sports Med. 2021;51(2):193–7. https://doi.org/10.1007/s40279-020-01387-5. (**Epub 2020 Dec 17 PMID: 33332013**).
8. Pedret C, Balius R, Blasi M, et al. Ultrasound classification of medial gastrocnemious injuries. Scand J Med Sci Sports. 2020;30:2456–65. https://doi.org/10.1111/sms.13812.
9. Nielsen L B, Svensson R B, Fredskild N U, et al. Chronic changes in muscle architecture and aponeurosis structure following calf muscle strain injuries. Scand J Med Sci Sports. 2023;33:2585–97. https://doi.org/10.1111/sms.14472.
10. Pezzotta G, Querques G, Pecorelli A, Nani R, Sironi S. MRI detection of soleus muscle injuries in professional football players. Skeletal Radiol. 2017;46(11):1513–20. https://doi.org/10.1007/s00256-017-2729-z. (**Epub 2017 Aug 2 PMID: 28770309**).
11. Martínez-Rodríguez R, Galán-Del-Río F, Cantalapiedra JA, Flórez-García MT, Martínez-Martín J, Álvaro-Meca A, et al. Reliability and discriminative validity of real-time ultrasound elastography in the assessment of tissue stiffness after calf muscle injury. J Bodyw Mov Ther. 2021;28:463–9. https://doi.org/10.1016/j.jbmt.2021.06.019. (**Epub 2021 Jun 17 PMID: 34776179**).
12. Green B, Lin M, McClelland JA, Semciw AI, Schache AG, Rotstein AH, et al. Return to play and recurrence after calf muscle strain injuries in elite Australian Football players. Am J Sports Med. 2020;48(13):3306–15. https://doi.org/10.1177/0363546520959327.
13. Green B, Lin M, Schache AG, McClelland JA, Semciw AI, Rotstein A, et al. Calf muscle strain injuries in elite Australian Football players: a descriptive epidemiological evaluation. Scand J Med Sci Sports. 2020;30(1):174–84. https://doi.org/10.1111/sms.13552. (**Epub 2019 Oct 8 PMID: 31494970**).
14. Pedret C, Rodas G, Balius R, Capdevila L, Bossy M, Vernooij RW, et al. Return to play after soleus muscle injuries. Orthop J Sports Med. 2015;3(7):2325967115595802. https://doi.org/10.1177/2325967115595802.PMID:26674181;PMCID:PMC4622332.
15. Sergot L, Kho J, Collins H, Williams J, Murray R, Chakraverty J. MRI classification of calf injuries - a reliability study and correlation with return to play in professional rugby players. Skeletal Radiol. 2023;52(1):61–6. https://doi.org/10.1007/s00256-022-04108-3. (**Epub 2022 Jul 30 PMID: 35907017**).
16. Waterworth G, Wein S, Gorelik A, Rotstein AH. MRI assessment of calf injuries in Australian Football League players: findings that influence return to play. Skeletal Radiol. 2017;46(3):343–50. https://doi.org/10.1007/s00256-016-2564-7. (**Epub 2017 Jan 16 PMID: 28093618**).
17. Werner BC, Belkin NS, Kennelly S, Weiss L, Barnes RP, Potter HG, Warren RF, Rodeo SA. Acute gastrocnemius-soleus complex injuries in national football league athletes. Orthop J Sports Med. 2017 Jan 11;5(1):2325967116680344. https://doi.org/10.1177/2325967116680344. Erratum in: Orthop J Sports Med. 2017 Jan 30;5(1):2325967117693882. https://doi.org/10.1177/2325967117693882. PMID: 28203595; PMCID: PMC5298443
18. Green B, McClelland JA, Semciw AI, Schache AG, McCall A, Pizzari T. The assessment, management and prevention of calf muscle strain injuries: a qualitative study of the practices and perspectives of 20 expert sports clinicians. Sports Med Open. 2022;8(1):10. https://doi.org/10.1186/s40798-021-00364-0.
19. Järvinen TA, Järvinen TL, Kääriäinen M, Kalimo H, Järvinen M. Muscle injuries: biology and treatment. Am J Sports Med. 2005;33(5):745–64. https://doi.org/10.1177/0363546505274714.
20. Leese PT, Hubbard RC, Karim A, Isakson PC, Yu SS, Geis GS. Effects of celecoxib, a novel cyclooxygenase-2 inhibitor, on platelet function in healthy adults: a randomized, controlled trial. J Clin Pharmacol. 2000;40(2):124–32. https://doi.org/10.1177/00912700022008766.
21. Fields KB, Rigby MD. Muscular calf injuries in runners. Curr Sports Med Rep. 2016;15(5):320–4. https://doi.org/10.1249/JSR.0000000000000292.
22. Alessandrino F, Balconi G. Complications of muscle injuries. J Ultrasound. 2013;16(4):215–22. https://doi.org/10.1007/s40477-013-0010-4.
23. Flecca D, Tomei A, Ravazzolo N, Martinelli M, Giovagnorio F. US evaluation and diagnosis of rupture of the medial head of the gastrocnemius (tennis

leg). J Ultrasound. 2007;10(4):194–8. https://doi.org/10.1016/j.jus.2007.09.007. (**Epub 2007 Oct 25. PMID: 23396898; PMCID: PMC3553076**).
24. Delgado GJ, Chung CB, Lektrakul N, Azocar P, Botte MJ, Coria D, et al. Tennis leg: clinical US study of 141 patients and anatomic investigation of four cadavers with MR imaging and US. Radiology. 2002;224(1):112–9. https://doi.org/10.1148/radiol.2241011067. (**PMID: 12091669**).
25. Rainbow C, Fields K (2024) Calf injuries not involving the Achilles tendon. UpToDate. Retrieved October 15, 2024 from https://www.uptodate.com/contents/calf-injuries-not-involving-the-achilles-tendon/abstract/3.
26. Orchard J, Best TM, Verrall GM. Return to play following muscle strains. Clin J Sport Med. 2005;15(6):436–41. https://doi.org/10.1097/01.jsm.0000188206.54984.65. (**PMID: 16278548**).
27. Sern-Kebschull J, Mechó S, Pedret C, et al. Muscle healing in sports injuries: MRI findings and proposed classification based on a single institutional experience and clinical observation. Radiographics. 2024;44(8):e230147. https://doi.org/10.1148/rg.230147. (**PMID: 39052498**).
28. Pollock N, Kelly S, Lee J, Stone B, Giakoumis M, Polglass G, et al. A 4-year study of hamstring injury outcomes in elite track and field using the British Athletics rehabilitation approach. Br J Sports Med. 2022;56(5):257–63. https://doi.org/10.1136/bjsports-2020-103791.
29. Page MJ, McKenzie JE, Bossuyt PM, Boutron I, Hoffmann TC, Mulrow CD, et al. The PRISMA 2020 statement: an updated guideline for reporting systematic reviews. BMJ. 2021;372:n71. https://doi.org/10.1136/bmj.n71.

Publisher's Note

Springer Nature remains neutral with regard to jurisdictional claims in published maps and institutional affiliations.